

MEASURES OF FEMORAL HEAD SHAPE IN PERTHES DISEASE USING 3D DATA SETS

Agnes G. d'Entremont PhD^{1,2*}, Carly E. Jones^{2,3}, David R. Wilson DPhil^{2,4}, Kishore Mulpuri MBBS^{2,4,5}

^{1*} *Department of Mechanical Engineering, University of British Columbia, Vancouver, V6T 1Z4, Canada, agnes.dentremont@mech.ubc.ca*

² *Centre for Hip Health and Mobility, University of British Columbia, Vancouver, V5Z 1M9, Canada*

³ *Department of Engineering Physics, University of British Columbia, Vancouver, V6T 1Z4, Canada*

⁴ *Department of Orthopaedics, University of British Columbia, Vancouver, V5Z 1M9, Canada*

⁵ *Department of Orthopaedic Surgery, BC Children's Hospital, Vancouver, V6H 3V4, Canada*

INTRODUCTION

Perthes disease is a childhood disorder that frequently results in residual femoral head deformity and subsequent cartilage degeneration (Snow et al. 1993; Larson et al. 2012). Assessment of deformity severity is important for clinical decision-making. Categorical or dichotomous outcomes of deformity are typical in clinical use (Mose 1980; Neyt et al. 1999), however they limit potential comparisons with continuous measures such as cartilage health or patient-reported outcome score, and may disguise important correlations. Quantitative, continuous measures of deformity are critical for studying treatments and interventions (Hosalkar and Mulpuri 2012).

The Sphericity Deviation Score (SDS) (Shah et al. 2013) is a continuous, quantitative measure of femoral head deformity in Perthes disease that uses radiographs in two planes. Limitations of this measure may include non-orthogonal planes due to joint positioning constraints or inaccuracies and lost details due to the projection imaging used. We explored applying and automating this type of method in 3D using CT images. Our specific objectives were to:

1. Develop sphericity measures from 3D data, based on SDS
2. Obtain 2D and 3D sphericity values for normal and Perthes hips from 3D data
3. Compare slice-based (3D) and projection-based (2D) measures of sphericity

METHODS

CT images of 16 normal (8 subjects) and 5 Perthes hips (4 subjects) were segmented semi-automatically (Analyze, Mayo Clinic) to create 3D hip models. Ethics board approval was obtained for this study.

We implemented two semi-automated, modified SDS (mSDS) versions in MATLAB (Mathworks): one version (2D-mSDS) used orthogonal projections (sagittal and coronal)

of the 3D model, similar to radiographic methods, and the second version (3D-mSDS) used slices with the largest radii in two orthogonal planes (sagittal and coronal) (Fig. 1). SDS is determined from the roundness error (RE) in two planes and the ellipsoid deformation (ED) between the two planes (Shah et al. 2013). RE circle centers were determined by best-fit circles (rather than by the manual landmarks used in the original implementation in radiographs).

Stulberg grades (I to V, based on the sphericity of the femoral head, the length of the femoral neck, the slope of the acetabulum, and the presence of coxa magna (Neyt et al. 1999)) were determined for each Perthes hip by one experienced paediatric orthopaedic surgeon, with Stulberg I being closest to normal geometry.

RESULTS

Mean 2D-mSDS was higher for Perthes than normal hips (Perthes 27.2 (SD 11.4); normals 11.9 (SD 4.1); Fig. 2). Mean 3D-mSDS showed similar trends between groups, but was higher overall compared to 2D measures (Perthes 33.6 (SD 5.3), normals 17.0 (SD 3.1)). Unlike 2D-mSDS, 3D-mSDS showed no overlap between the groups. 3D-mSDS values were significantly higher than 2D-mSDS values over all hips (paired t-test, $p < 0.001$), with mean difference of 5.4 points.

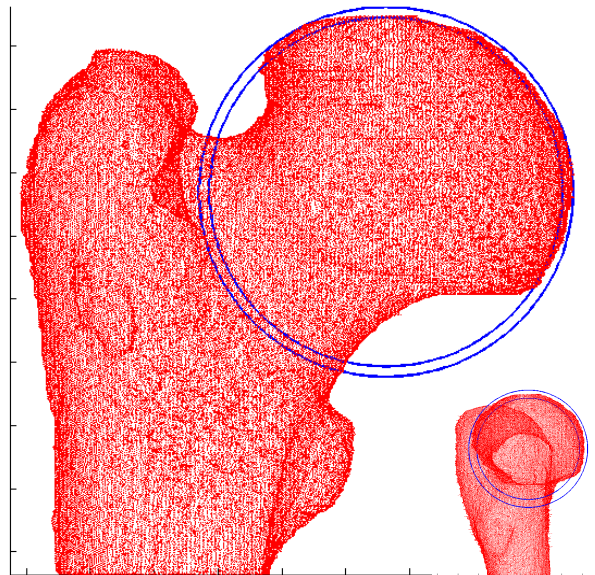


Figure 1: Slice-based (3D) SDS measuring roundness error (RE) on a Stulberg class II Perthes hip (coronal plane view, with sagittal plane view inset).

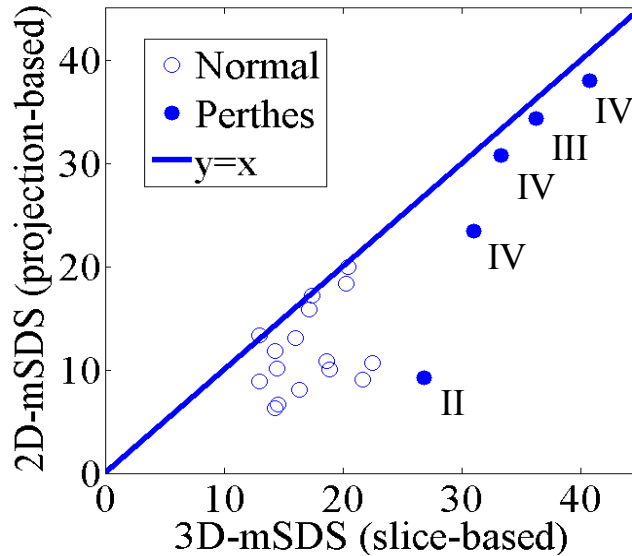


Figure 2: Projection-based (2D) vs. slice-based (3D) mSDS measure. Mean 3D-mSDS is higher than 2D-mSDS in normal and Perthes groups, and there is no overlap between groups in the 3D-mSDS method. Stulberg grade is displayed for Perthes hips.

DISCUSSION

After developing and implementing two variations of a sphericity measure obtained from 3D data and applying the measures to normal and Perthes hip CTs, we found that 2D-mSDS values were generally consistent with the original projection-based SDS (mean Stulberg II: 4.06; mean Stulberg III: 21.99; mean Stulberg IV: 43.34 (Shah et al. 2013)) for Perthes hips.

Projection-based (2D) measures likely produce lower mSDS due to spatial averaging of deformities visible in each slice. Slice-based (3D) measures may better distinguish between normal and Perthes head shapes, particularly at lower Stulberg grades. Analysis of further images, especially grade I and II hips, will be required to determine sample sizes needed to assess this possible differentiation.

2D-mSDS values for normal hips, which have not been reported previously, were higher than expected (similar to SDS results for Stulberg II or III hips (Shah et al. 2013) and 2D-mSDS results for Stulberg II hips).

SDS and mSDS use a small fraction of available data points to provide a measure of 3D deformity (though mSDS uses all perimeter data to find head centre). Further work will include investigating measures that use more of the available 3D shape data.

The original SDS method, applied at the healing stage of Perthes disease, has shown an association with outcomes at skeletal maturity (Siddesh et al. 2014). From our results, it is possible that a slice-based (3D) method may better capture small deformity features, and may further advance the prognostic value of this measure and its usefulness in determining the effectiveness of surgical and conservative treatment.

REFERENCES

- Hosalkar HS, Mulpuri K (2012) Legg-Calvé-Perthes disease: where do we stand after 100 years? Editorial comment. *Clin Orthop Relat Res* 470:2345–6. doi: 10.1007/s11999-012-2418-0
- Larson AN, Sucato DJ, Herring JA, et al. (2012) A Prospective Multicenter Study of Legg-Calve-Perthes Disease. *J Bone Jt Surg Am* 94:584–592.
- Mose K (1980) Methods of measuring in Legg-Calvé-Perthes disease with special regard to the prognosis. *Clin Orthop Relat Res* 103–9.
- Neyt JG, Weinstein SL, Spratt KF, et al. (1999) Stulberg Classification System for Evaluation of Legg-Calvé-Perthes Disease: Intra-Rater and Inter-Rater Reliability. *J Bone Jt Surg Am* 81-A:1209–1216.
- Shah H, Siddesh ND, Pai H, et al. (2013) Quantitative Measures for Evaluating the Radiographic Outcome of Legg-Calve-Perthes Disease. *J Bone Jt Surg Am* 95:354–361.
- Siddesh ND, Shah H, Tercier S, et al. (2014) The Sphericity Deviation Score: A Quantitative Radiologic Outcome Measure of Legg-Calvé Perthes Disease Applicable at the Stage of Healing and at Skeletal Maturity. *J Pediatr Orthop* 00:1–7. doi: 10.1097/BPO.0000000000000170
- Snow SW, Keret D, Scarangella S, Bowen JR (1993) Anterior Impingement of the Femoral Head: a Late Phenomenon of Legg-Calve-Perthes' Disease. *J Pediatr Orthop* 13:286–289.

DISCLOSURES

The authors have no relationships to disclose.