

# **EFFECTS OF MICRO-ARC OXIDATION COATING ON OUTCOMES OF A CEMENTLESS GRIT-BLASTED TAPERED-WEDGE STEM IN TOTAL HIP ARTHROPLASTY**

Seung-Jae Lim MD, In-Kwon Yeo MD, Su-Cheol Kim MD, and Yoon-Soo Park MD\*  
\*Department of Orthopaedic Surgery, Samsung Medical Center, Sungkyunkwan University School of Medicine, Seoul, 135-710, South Korea, limsj70@gmail.com

## **INTRODUCTION**

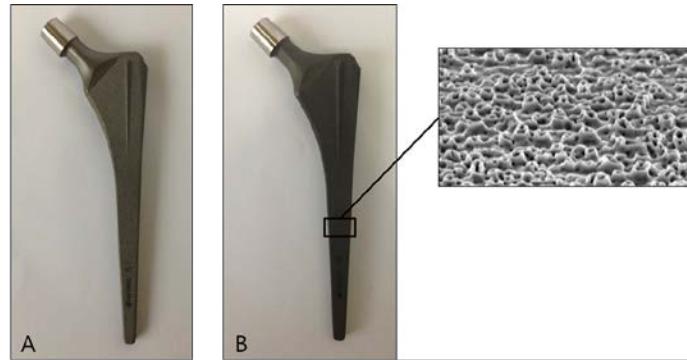
Micro-arc oxidation (MAO) is an electrochemical method used to treat metal surfaces. It provides nanoporous pits, and thick oxide layers, and incorporates calcium and phosphorus into the coating layer of titanium alloy. This modification on the surface of titanium alloy by MAO coating would improve the ability of cementless stems to osseointegrate. In spite of these structural and chemical advantages, clinical study of total hip arthroplasty (THA) using MAO coated stem has not yet been reported. In this study, we evaluated the clinical and radiographic results associated with cementless grit-blasted tapered-wedge stems that were identical in geometry but differed with regard to surface treatment with or without MAO coating.

## **MATERIALS AND METHODS**

We performed a retrospective review of 141 THAs using MAO coated stem for a minimum of 5 years and compared them to 219 THAs using the same geometry stem without MAO coating. A cementless Bencox femoral component was used in all hips. It is made of titanium alloy with a straight, double wedged, tapered stem with a rectangular cross-section. Surface treatment was performed using grit blasting with a roughness of 5.5 $\mu$ m that was available either with or without MAO coating. Clinical and radiographic evaluations were performed preoperatively and at 6 weeks, 3 months, 6 months, and 1 year postoperatively, and then annually.

## **RESULTS**

In the MAO coating group, the mean Harris hip score improved from 43.7 points preoperatively to 93.9 points postoperatively. The mean WOMAC score and UCLA activity score at the final follow-up was 17 points (range, 6-34 points) and 6.9 points (range, 5-10 points), respectively. Thigh pain at final follow-up was reported in 2 hips (1.4%), but neither of these hips showed signs of implant loosening or limited daily activities. Complications included one squeaking, one iliopsoas tendonitis, and one deep vein thrombosis. Postoperative Harris hip scores, WOMAC scores, UCLA activity scores, and complication rates did not differ between the two groups. In both groups, no femoral or acetabular component showed radiographic evidence of mechanical loosening, and no components had been revised at the final follow-up.



**Figure 1: Frontal view of Bencox femoral stems. Surface treatment was performed using grit blasting with a roughness of 5.5 $\mu$ m that was available either without MAO coating (A) or with MAO coating (B)**

## **DISCUSSION**

Primary THA using a cementless grit-blasted tapered-wedge stem with MAO coating showed encouraging medium-term outcomes. Further prospective controlled study is required to investigate the long-term implant survival, possible complications, and cost-effectiveness of utilizing MAO coating in THA.

## **REFERENCES**

- Li LH, Kong YM, Kim HW, Kim YW, Kim HE, Heo SJ, Koak JY, Improved biological performance of Ti implants due to surface modification by micro-arc oxidation. *Biomaterials*, 25(14), pp. 2867-2875, 2004.
- Lim YW, Kwon SY, Sun DH, Kim HE, Kim YS, Enhanced cell integration to titanium alloy by surface treatment with microarc oxidation: a pilot study. *Clin Orthop Relat Res*, 467(9), pp. 2251-2258, 2009.
- Lim YW, Kwon SY, Sun DH, Kim YS, The Otto Aufranc Award: enhanced biocompatibility of stainless steel implants by titanium coating and microarc oxidation. *Clin Orthop Relat Res*, 469(2), pp. 330-338, 2011.
- Müller LA, Wenger N, Schramm M, Hohmann D, Forst R, Carl HD, Seventeen-year survival of the cementless CLS Spotorno stem. *Arch Orthop Trauma Surg*, 130(2), pp. 269-275, 2010.
- Ström H, Nilsson O, Milbrink J, Mallmin H, Larsson S, Early migration pattern of the uncemented CLS stem in total hip arthroplasties. *Clin Orthop Relat Res*, 454(1), pp. 127-132, 2007.

## **DISCLOSURES**

None